

Surgical treatment of oral leukoplakia using Er:YAG Laser – Case report

Duarte F¹, Ramos C²

Affiliations:

1.CEO and Clinical Director of Clitrofa - Trofa, Portugal.

Oral Surgeon Specialist by OMD (Portuguese Dental Association)

2. MSc student in Oral Oncology at Instituto de Ciências Biomédicas Abel Salazar - Oporto University – Portugal

Corresponding author:

Fernando Duarte

Clitrofa - Centro Médico, Dentário e Cirúrgico

fduarte@clitrofa.com

ABSTRACT

Purpose: Leukoplakia is a clinical term indicating a white patch or plaque of oral mucosa that cannot be rubbed off and cannot be characterized clinically as any other disease. Leukoplakias may have similar clinical appearances, but have a considerable degree of microscopic heterogeneity. Because leukoplakias may range microscopically from benign hyperkeratosis to invasive squamous cell carcinomas, a biopsy is mandatory to establish a definitive diagnosis.

Case Report: This paper will present a case report of a 63-year-old male patient, caucasian, attended the Oral-Maxillofacial Surgery consultation at Clitrofa - Centro Médico, Dentário e Cirúrgico, in Trofa - Portugal, to evaluate a white lesion in the left jugal mucosa. The treatment plan was based on anatomopathological report indicative of leukoplakia. It was decided to carry out surgical treatment of the lesion using LightWalker® Er:YAG laser from Fotona. Local anaesthetic was infiltrated into the soft tissue surrounding the lesion (Lidocaine/ Epinephrine 20 mg/ml + 0.0125 mg/ml solution for injection EFG). The Er:YAG handpiece R16 was used, 3.6 J/cm² Energy, 10 Hz Frequency, 13.8 W Power, LP Mode.

Conclusion: After a 12-month follow-up period, the patient is pain free and the lesion has no signs of recurrence. Er:YAG laser may be considered a successful treatment modality for oral leukoplakia.

KEYWORDS

Leukoplakia, Er:YAG laser

INTRODUCTION

Oral leukoplakia is defined by the World Health Organization (WHO) as “a white patch or plaque that cannot be characterized clinically or pathologically as any other disease”. The term is strictly a clinical one and does not imply a specific histopathologic tissue alteration, it is typically considered to be a precancerous or premalignant lesion. This excludes lesions such as lichen planus, candidiasis, leukoedema, white sponge nevus, and obvious frictional keratosis.¹

Leukoplakias may have similar clinical appearances, but have a considerable degree of microscopic heterogeneity. Because leukoplakias may range microscopically from benign hyperkeratosis to invasive squamous cell carcinomas, a biopsy is mandatory to establish a definitive diagnosis.²

ETIOLOGY AND PATHOGENESIS

Many cases of leukoplakia are etiologically related to the use of tobacco in smoked or smokeless forms, and many regress after discontinuation of tobacco use. Other factors, such as alcohol abuse, trauma, and *Candida albicans* infection, may have a role in the etiology of leukoplakia. Nutritional factors have also been cited as important, especially relative to iron deficiency anaemia and development of sideropenic dysphagia (Plummer-Vinson or Paterson-Kelly syndrome).^{1,3}

Rates of transformation to squamous cell carcinoma have varied from study to study as a result of differences in the underlying pathology and difference in the use of putative carcinogens such as tobacco. Geographic differences in the transformation rate, as well as in the prevalence and location of oral leukoplakias, are likely related to the differences in tobacco habits in various parts of the world. Approximately 5% of leukoplakias are malignant at the time of first biopsy, and approximately 5% of the remainder undergo subsequent malignant transformation. From 10% to 15% of the dysplasias that present as clinical leukoplakias will develop into squamous cell carcinoma. There are wide ranges of risk of transformation from one anatomic site to another, such as the floor of the mouth, where transformation rates are comparatively high, although paradoxically many shows only minimal amounts of epithelial dysplasia.^{1,2,3,4}

CLINICAL FEATURES

Leukoplakia is a condition associated with a middle-aged and older population. The vast majority of cases occur after the age of 40 years. Over time there has also been a shift in gender predilection, with near parity in the incidence of leukoplakia, apparently as a result of the change in smoking habits of women.¹ Predominant sites of occurrence have changed through the years. At one time, the tongue was the most common site for leukoplakia, but this area has given way to the mandibular mucosa and the buccal mucosa, which account for almost half of the leukoplakias. The palate, maxillary ridge, and lower lip are somewhat less often involved, and the floor of the mouth and retromolar sites are less often involved.^{1,4}

The relative risk of neoplastic transformation varies from one anatomic region to another. Although the floor of the mouth accounts for a relatively small percentage (10%) of leukoplakias, a large percentage are found to be dysplastic, carcinoma in situ, or invasive carcinoma when examined microscopically. Leukoplakia of the lips and tongue also exhibits a relatively high percentage of dysplastic or neoplastic change. In contrast to these locations, the retromolar are exhibits these changes in only 10% of cases.¹

On visual examination, leukoplakia may vary from a barely evident, vague whiteness on a base of uninfamed,

normal-appearing tissue to a definitive white, thickened, leathery, fissured, verrucous (wartlike) lesion. Red zones may also be seen in some leukoplakias, prompting use of the term speckled leukoplakia (erythroleukoplakia). On palpation, some lesions may be soft, smooth, or finely granular. Other lesions may be roughened, nodular or indurated.^{3,4}

Proliferative verrucous leukoplakia has been segregated from other leukoplakias; this type of leukoplakia begins as simple keratosis and eventually becomes verrucous in nature. Lesions tend to be persistent, multifocal, and sometimes aggressive. Recurrence is common. The diagnosis is determined clinicopathologically and is usually made retrospectively. Malignant transformation to verrucous or squamous cell carcinoma is seen in more than 15% of cases.³

HISTOPATHOLOGY

The term dysplasia indicates abnormal epithelium and disordered growth, whereas atypia refers to abnormal nuclear features. Increasing degrees of dysplasia are designated as mild, moderate and severe and are subjectively determined microscopically. Specific microscopic characteristics of dysplasia include (1) drop-shaped epithelial ridges, (2) basal cell crowding, (3) irregular stratification, (4) increased and abnormal mitotic figures, (5) premature keratinization, (6) nuclear pleomorphism and hyperchromatism, and (7) an increased nuclear-cytoplasmic ratio.^{1,2}

It is generally accepted that the more severe the epithelial changes, the more likely a lesion is to evolve into cancer. However, there is no way microscopically to predict which dysplasias, mild to severe, will progress to squamous cell carcinoma. When the entire thickness of epithelium is involved with the changes in a so-called top-to-bottom pattern, the term carcinoma in situ may be used when cellular atypia is particularly severe, even though the changes may not be evident from basement membrane to surface. Carcinoma in situ is not regarded as a reversible lesion, although it may take many years for invasion to occur. A majority of squamous cell carcinomas of the upper aerodigestive tract, including the oral cavity, are preceded by epithelial dysplasia. Conceptually, invasive carcinoma begins when a microfocus of epithelial cell invades the lamina propria 1 to 2 mm beyond the basal lamina. At this early stage, the risk of regional metastasis is low.^{1,2}

DIFFERENTIAL DIAGNOSIS

The first step in developing a differential diagnosis for a white patch on the oral mucosa is to determine whether the lesion can be removed with a gauze square or tongue blade.^{1,2,3,4}

If the lesion can be removed, it represents a pseudomembrane, fungus colony, or debris. If there is evidence of bilateral buccal mucosa disease, hereditary conditions, cheek chewing, lichen planus, and lupus erythematosus should be considered.¹

Concomitant cutaneous lesions would give weight to the latter two. If either chronic trauma or tobacco-associated hyperkeratosis should be considered, respectively. Elimination of a suspected cause should result in some clinical improvement. Also included in differential diagnosis for tongue leukoplakia would be hairy leukoplakia and geographic tongue.^{1,4}

If the lesion in question is not removable and is not clinically diagnostic, it should be considered an idiopathic leukoplakia and a biopsy should be performed. For extensive lesions, multiple biopsies may be necessary to avoid sample error. The clinically most suspicious areas (red, ulcerated, or indurated areas) should be included in the area to be biopsied.^{1,4}

TREATMENT AND PROGNOSIS

In the absence of dysplastic or atypical epithelial changes, periodic examinations and rebiopsy of new suspicious areas are recommended. If a lesion is mildly dysplastic, some clinical judgment should be exercised in patient management. Potential etiologic factors should be considered. Removal of mildly dysplastic lesions is in the patient's best interest if there is no apparent causative factor, and the lesion is small. If considerable morbidity would result because of the lesion's size or location, follow-up surveillance is acceptable.^{1,8}

If leukoplakia is diagnosed as moderate to severe dysplasia, removal becomes obligatory. Various surgical methods such as scalpel excision, cryosurgery, electrosurgery and laser surgery seem to be equally effective in ablating these lesions. For large lesions, grafting procedures may be necessary after surgery. It is important to note that many idiopathic leukoplakias may recur after complete removal. It is unlikely to predict which lesions will return and which will not.^{1,2,3,4}

CLINICAL CASE

A 63-year-old male patient, caucasian, attended the Oral-Maxillofacial Surgery consultation at Clitrofa - Centro Médico, Dentário e Cirúrgico, in Trofa - Portugal, to evaluate a white lesion in the left jugal mucosa. The patient has been generally healthy, with no serious illnesses; there was no allergies or use of medications. On extraoral clinical examination, an aspect of normality was observed.

On intraoral clinical examination, was observed an extensive white lesion (+/- 2 cm), irregular with well-defined edges at the level of the buccal mucosa of the 3rd quadrant and with intercalated erythroplastic zones. It is not related to occasional trauma, nor does it stand out easily. Lesion with evolution of about 1 year, but without symptomatology (Figure 1).

An incisional biopsy was performed and in the evaluation of

pathological anatomy, the histological examination revealed a mucosa covered by stratified squamous epithelium with marked acanthosis and ortho and parakeratotic hyperkeratosis. Focal spongiosis, vacuolar degeneration of basal keratinocytes and occasional basal keratinocytes were identified. In the chorion, a band of lymphocytic inflammatory infiltrate was observed, which focally permeates the lining epithelium.

Focal lesions of low-grade dysplasia were also identified. No signs of malignancy were observed.

Based on the anatomopathological report indicative of leukoplakia, it was decided to carry out surgical treatment of the lesion using LightWalker® Er:YAG laser.

The Er:YAG was used, because it vaporizes the lesion through its photothermal effect on water molecules. It completely absorbs into superficial tissue layer and such prevented damage to the surrounding structures. This is important when removing deeper layers around nerves and vessels. The control of bleeding is higher with Nd:YAG, but Er:YAG is safer. A longer pulse (LP mode) presents a higher risk of thermal damage to the hard tissue, but allows deeper penetration for the increasing degrees of dysplasia.

Laser treatment approach: Local anaesthetic was infiltrated into the soft tissue surrounding lesion (Lidocaine/ Epinephrine 20 mg/ml + 0.0125 mg/ml solution for injection EFG). The Er:YAG handpiece R16 was used, 3.6 J/cm² Energy, 10 Hz Frequency, 13.8 W Power, LP Mode.

The patient had a postoperative period with no pain and local edema. Anti-inflammatory analgesic (100 mg nimesulide for 6 days) was prescribed.

After the first laser session, the lesion was not completely excised and a second session was necessary 30 days later, only in the areas that showed some degree of dysplasia. In both sessions, the same protocol described was used (Figure 2).

After a 12-month follow-up period, the patient is pain free and the lesion has no signs of recurrence (Figure 3).

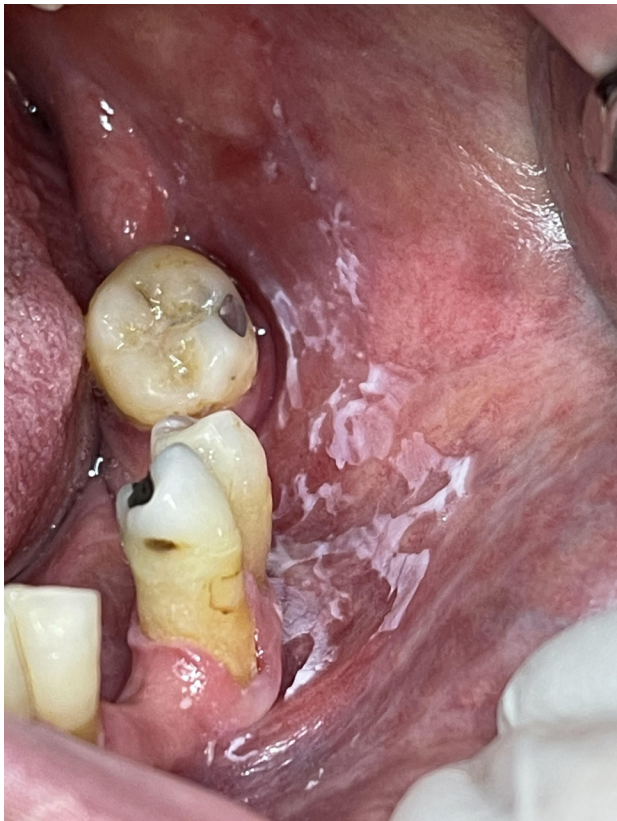


Figure 1. Initial aspect of the lesion

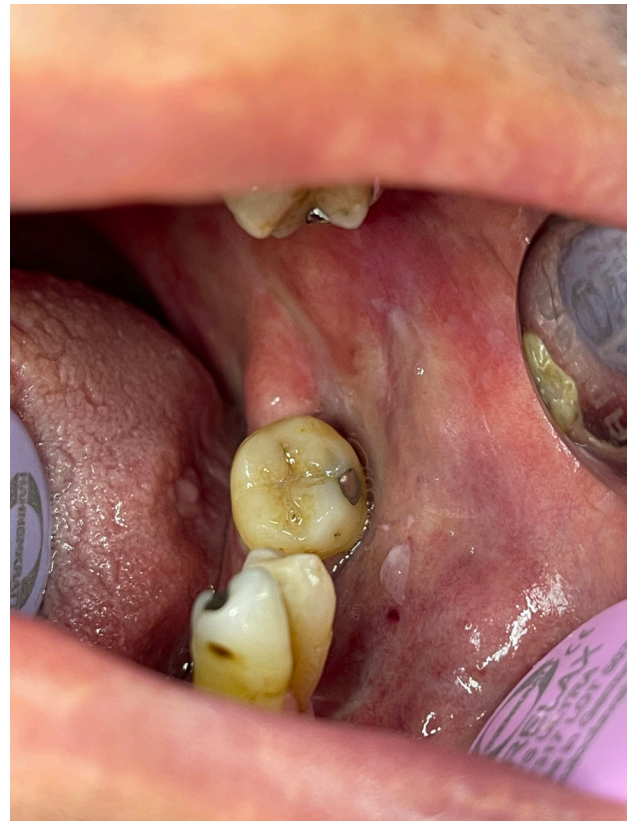

Figure 2. Clinical aspect after first laser session

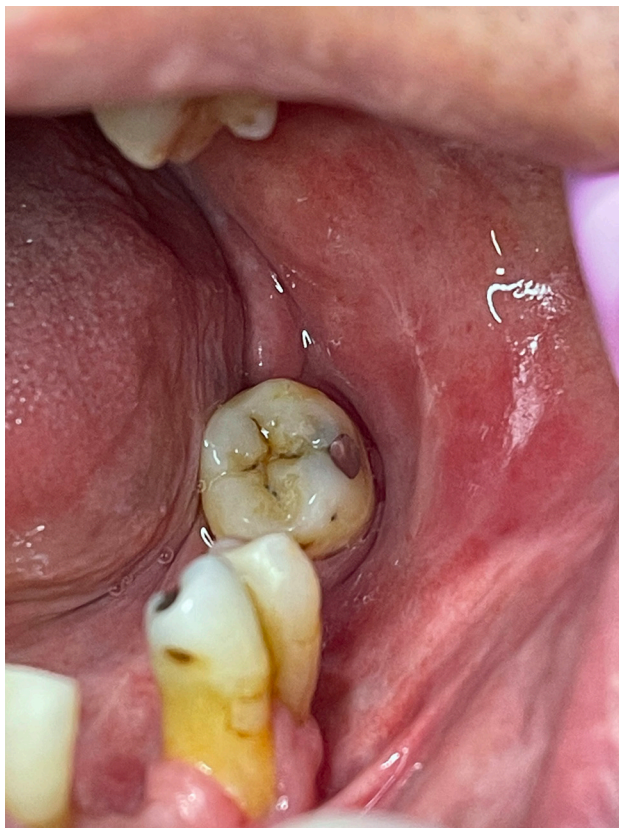


Figure 3. Final aspect of the lesion with 12 months of follow-up

DISCUSSION

Leukoplakia represents a clinical term only, the first step in treatment is to arrive at a definitive histopathologic diagnosis. Therefore, a biopsy is mandatory and will guide the course of treatment. Tissue obtained for biopsy, moreover, should be taken from the clinically most “severe” areas of involvement. Multiple biopsies of large or multiple lesions may be required.^{1,8} Leukoplakia exhibiting moderate epithelial dysplasia or worse warrants complete destruction or removal, if feasible. The management of leukoplakia exhibiting less severe change is guided by the size of the lesion and the response to more conservative measures, such as smoking cessation.^{1,2,3,4} Complete removal can be accomplished with equal effectiveness by surgical excision, electrocautery, cryosurgery, or laser ablation. Long-term follow-up after removal is extremely important because recurrences are frequent and because additional leukoplakias may develop.^{1,2,3,4}

In a study that considers one hundred seventeen lesions treated, fifty-eight lesions underwent surgery with traditional scalpel, whereas 59 underwent laser surgery⁵. Follow-up ranged from 24 to 108 months (median of 58). Healing was detailed for 52.99% (n=62) of the 117 oral leukoplakia, with no statistical differences between the two randomized groups. It seems reasonable to consider the Er:YAG laser as effective as traditional scalpel in terms of healing for oral leukoplakia, with the same rate of recurrences in a period of almost 5 years.⁵

In another study, with a sample consisted of 54 patients (16 men and 38 women) who were histopathologically diagnosed with oral leukoplakia that was refractory to conventional retinoid therapy⁶. Patients were randomly allocated into two groups according to the type of the laser used for treatment of oral leukoplakia: Group 1 Er:YAG laser; Group 2 Er,Cr:YSGG laser. Patients were recalled at 6 months and 1 year after treatment to evaluate possible recurrence and assess the patient's postoperative quality of life. In the results after initial ablation, the degree of residual lesion was significantly greater in the Er:YAG laser group (74.1%), compared with the Er,Cr:YSGG group (18.5%) (p=0.0001). Six months and 1 year after the second ablation, there was no lesion recurrence in either laser group. Fourteen days after the initial ablation, the visual analogue scale (VAS) pain rating and the total oral health impact profile score fell significantly in both groups (p<0.0001). However, in the Er,Cr:YSGG laser group, the average value of the VAS rating was significantly lower than in the Er:YAG laser group (p=0.039). The Er:YAG and Er,Cr:YSGG lasers showed similar efficacy in the treatment of oral leukoplakia and resulted in full postoperative recovery without recurrence after 1 year of follow-up.^{6,8}

CONCLUSION

Laser technology has certain advantages such as accuracy of the incision, absence of vibration and manual pressure during use. Due to laser positive coagulation effects during surgical procedure, better sight of the work field is obtained. Furthermore, risk of surgical field contamination and damage to the surrounding tissues is decreased when compared to the other similar techniques. Additionally, Er:YAG lasers are characterized by low intraoperative and postoperative pain levels and produce rapid wound healing. Er:YAG laser may be considered a successful treatment modality for oral leukoplakia.

CONFLICT OF INTEREST

The authors declares that there is no conflict of interest regarding the publication of this article.

REFERENCES

- Villa A, Sonis S. Oral leukoplakia remains a challenging condition. *Oral Dis* 2018 Mar;24(1-2):179-183.
- Sciubba JJ. Oral precancer and cancer: etiology, clinical presentation, diagnosis, and management. *Compend Contin Educ Dent* 2000 Oct;21(10A):892-898.
- Hyde N, Hopper C. Oral cancer: the importance of early referral. *Practitioner* 1999 Oct;243(1603):753, 756-8.
- Rhodus NL, Kerr AR, Patel K. Oral cancer: leukoplakia, premalignancy, and squamous cell carcinoma. *Dent Clin North Am* 2014 Apr;58(2):315-340.
- Arduino PG, Cafaro A, Cabras M, Gambino A, Broccoletti R. Treatment Outcome of Oral Leukoplakia with Er:YAG Laser: A 5-Year Follow-Up Prospective Comparative Study. *Photomed Laser Surg* 2018 Dec;36(12):631-633
- Matulić N, Bago I, Sušić M, Gjorgjevska E, Knežević AK, Gabrić D. Comparison of Er:YAG and Er,Cr:YSGG Laser in the Treatment of Oral Leukoplakia Lesions Refractory to the Local Retinoid Therapy. *Photobiomodul Photomed Laser Surg* 2019 Jun;37(6):362-368
- Gabrić D, Brailo V, Ivek A, Krpan K, Matulić N, Vrdoljak DV, Baraba A, Boras VV. Evaluation of innovative digitally controlled Er:YAG laser in surgical treatment of oral leukoplakia – A preliminary study. *Acta Clin Croat* 2019 Dec;58(4):615-620
- Del Corso G, Gissi DB, Tarsitano A, Costabile E, Marchetti C, Montebugnoli L, Foschini MP. Laser evaporation versus laser excision of oral leukoplakia: A retrospective study with long-term follow-up. *J Craniomaxillofac Surg* 2015 Jul;43(6):763-8